

# High-Risk Beating Heart Coronary Revascularization Facilitated by Percutaneous Transseptal Ventricular Assistance (PTVA®)

Based on a case report by Jeffrey Moses, MD, Gary Roubin, MD, Valvanur Subramanian, MD, Jim Fonger, MD, Lenox Hill Hospital, New York, NY

---

## Abstract

*A 56 year old male patient in cardiogenic shock failed to recover on full pressor support and IABP therapy. Selective cineangiography revealed multi-vessel coronary artery disease including high grade left main stenosis and a totally occluded left anterior descending coronary artery. Percutaneous ventricular assistance with the TandemHeart™ pVAD was employed to reverse shock before surgery. A quintuple bypass procedure on the beating heart was performed with continued TandemHeart support.*

---

## Introduction

Over the past two decades advances in reperfusion therapy have significantly reduced the mortality rate and the number of complications associated with acute myocardial infarction (MI). Nevertheless, even today, cardiogenic shock (CS) remains a leading cause of death in patients hospitalized with acute MI<sup>1</sup>.

The pathophysiology of CS involves a vicious circle that perpetuates the thinning and dilation of the infarcted zone and the extension of the infarcted area. As left ventricular (LV) function worsens, hypoperfusion of both the infarcted as well as the non-infarcted myocardium propagates<sup>2</sup>. Treatments to break this vicious circle most commonly include pharmacological support with vasopressors and inotropic agents. An IABP may serve as a bridge to coronary revascularization. When aggressive medical management of CS fails, long term use of a ventricular assist device may be indicated<sup>3</sup>. However, all currently available short and long term ventricular assist devices require extensive surgery for implantation and explantation. The critical condition of patients in CS may prevent such a course of treatment. A new ventricular assist device (TandemHeart pVAD System, CardiacAssist, Inc. Pittsburgh, PA) has been designed for rapid percutaneous institution of support without the need for surgery. The TandemHeart was designed to deliver substantial left ventricular assistance with flow rates of up to 4 L/min.

## Case Report


A 56-year-old male patient experienced chest pain and shortness of breath. When paramedics arrived at his home he was in acute respiratory distress, and was intubated shortly thereafter. The patient was treated in the field with nitrates, and transported to the closest hospital with continued chest pain, and EKG changes in lead III and V. Intra aortic balloon therapy was initiated in the ER. The patient

was transferred to Lenox Hill on the balloon pump. In spite of pharmacological and IABP treatment the patient went into cardiogenic shock. The TandemHeart pVAD System was determined to be the only viable option to reverse cardiogenic shock and to allow time to plan the next course of therapy.

Prior to the procedure the patient's sedation was reduced and he was appropriately responsive. His cardiac output (CO) was 4.0 L/min and the cardiac index (CI) 1.8 L/min/m<sup>2</sup>. He had a mean arterial pressure (MAP) of 72 mmHg at a heart rate (HR) of 84 BPM.

The intra-aortic balloon was removed and exchanged for an arterial sheath. A Swan-Ganz catheter was also in place in the left groin. The Swan was temporarily removed for the implantation procedure. Pressor support was transiently interrupted and systolic blood pressure decreased to 40 mmHg. Access was gained to the right femoral artery and vein using standard percutaneous technique. The inter atrial puncture was performed with a standard transseptal puncture kit (Brockenbrough needle, Mullen sheath). A 0.025" pigtail guidewire was inserted into the left atrium. A two-stage dilator (14/21 French) was advanced over the guidewire to dilate the puncture site. The dilator was then exchanged with a 21 French transseptal cannula to allow drainage of the left atrium. A single 15 French femoral arterial cannula was selected for blood return and introduced percutaneously. The blood circuit assembly was then completed and de-aired, and support was initiated (see Figure 1.) The patient's vital signs immediately improved to the following values: blood pressure (BP) 102/76 mmHg, MAP 83 mmHg, HR 80 BPM, CO 5.9 L/min, and CI 2.8 L/min/m<sup>2</sup>.

With the patient stabilized on TandemHeart support, selective coronary cineangiography was performed. The examination revealed a left dominant coronary vasculature. The



(Figure 1.) TandemHeart pVAD in operation with single arterial cannulation

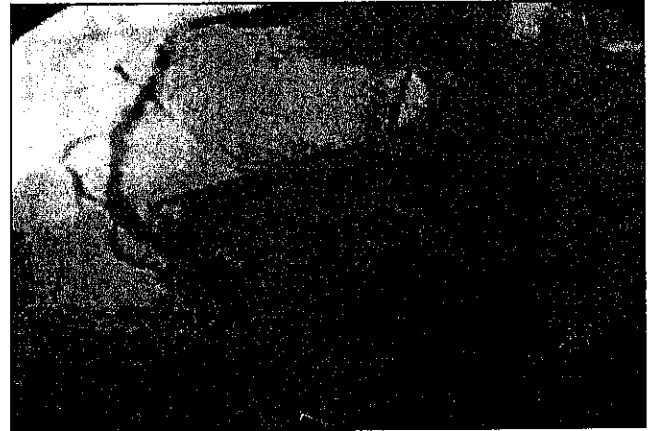left main coronary artery showed 80% stenosis with a totally occluded LAD, and a high-grade circumflex lesion. The right coronary artery (RC) showed diffuse disease with a graftable distal target. The lateral wall showed a single obtuse marginal branch with a high grade proximal stenosis. The left ventricular function was severely depressed with an ejection fraction (EF) of 10-15%. See Figures 2. to 4. As a result of these findings, the cardiologists determined that CABG surgery would be the best option.



(Figure 2.) High grade left main disease


The patient was transferred without incident to the CCU where he remained stable throughout the night. He was resistant to heparin, and required doses over 1500 U/hr with additional bolus's to maintain an ACT of over 200 seconds. Presence of "coffee ground" NG tube drainage also complicated but did not compromise his therapeutic course. Throughout the first 48 hours of support the patient required pharmacological support with moderate doses of Dopamine and minimal doses of Levophed. These doses were steadily

reduced throughout his CCU stay, and may have been required as a result of the medication given to maintain the current level of sedation (Propofol). It was decided to keep the patient sedated to prevent him from moving his extremities.



(Figure 3.) Right coronary artery with diffuse disease throughout its course.

On the second day after initiation of support the patient's CO had improved to 6.0 L/min with a CI of 2.8 L/min/m<sup>2</sup>. He had a low-grade fever throughout his CCU stay and was maintained on wide spectrum IV antibiotics. At the beginning of day three of support, the patient was reliant only on small doses of dopamine for optimal pressures. TandemHeart support was temporarily discontinued for cardiac assessment. The patient's systolic pressure remained between 95 to 99 mmHg with a CO of 4.7 L/min, a CI of 2.2 L/min/m<sup>2</sup>, and a HR of 77 BPM. At this time substandard quality bedside echocardiography indicated an EF of 10%, with mild mitral valve regurgitation (MR) and no effusion. CK levels had reached a level of 1.2 mg/dL. Surgery was




(Figure 4.) Severely depressed ventricular function

planned for the following day.

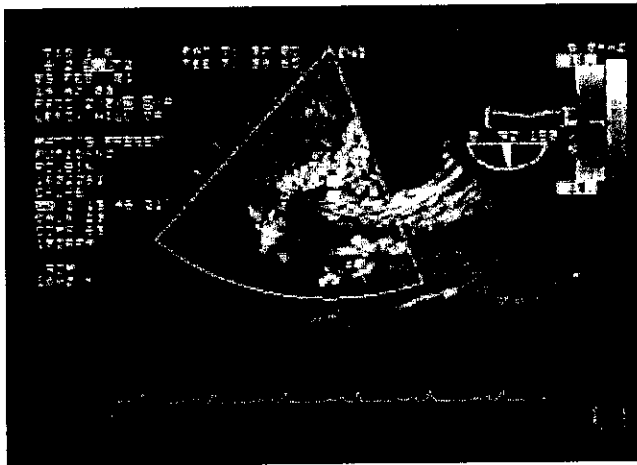
On the fourth day, the patient was transferred to the operat-

ing room. The decision was made to keep him on Tandem-Heart support while quintuple bypass grafting was performed on the beating heart. Color flow doppler performed immediately prior surgery showed markedly depressed left ventricular function and a grade II<sup>+</sup> MR (Figure 5.).



(Figure 5.) Grade II<sup>+</sup> Mitral valve regurgitation

During surgery the pump delivered a steady flow of more than 3 L/min allowing the heart to be manipulated to expose lateral and posterior vessels. Figure 6. shows blood entering the tip of the transeptal cannula. The TandemHeart was removed in the OR immediately following surgery. The cannulation sites were closed by applying manual pressure. The patient remained in the hospital for two weeks to mobilize him and to begin rehabilitation. Several weeks later he had recovered to a point where he was able to walk several blocks.



(Figure 6.) Blood entering the Transseptal Cannula

## Discussion

Patients in cardiogenic shock after acute MI and with severe multi-vessel disease are in critical need for hemodynamic stabilization and revascularization. In this case, the IABP

did not provide the required amount of ventricular support to reverse shock or to prevent end organ hypoperfusion. At the same time, the extent of the patient's coronary disease did not allow percutaneous revascularization. The severely depressed ventricular function and the cardiogenic shock condition prevented immediate surgical intervention to revascularize or to implant a long-term VAD. The Tandem-Heart proved to be the ideal tool to stabilize the patient hemodynamically and to reverse cardiogenic shock and its effects on end-organ perfusion without subjecting the patient to an extensive surgical implantation procedure. During beating heart surgery the TandemHeart provided hemodynamic stability even during vigorous manipulation of the heart to reach lateral and posterior vessel targets. The TandemHeart System makes percutaneous ventricular assistance a viable option for patients in cardiogenic shock.

## Acknowledgement

We wish to acknowledge Drs. Moses, Subramanian, and Fonger for their assistance in developing this case report and for their participation in the US clinical trial series for the clearance of the TandemHeart pVAD System.

## References

- 1 Becker RC, Gore JM, Lambrew C, Weaver WD, Rubison RM, French WJ, Tiefenbrunn AJ, Bowlby LJ, Rogers WJ. A composite view of cardiac rupture in the United States National Registry of Myocardial Infarction. *J Am Coll Cardiol* 1996; 27: 1321-6
- 2 Califf, RM, ed., "Atlas of Heart Diseases. Acute Myocardial Infarction and Other Acute Ischemic Syndromes", Vol VIII, Mosby, St. Louis, 1996, 12.1
- 3 Marso SP, Griffin BP, Topol EJ, ed., "Manual of Cardiovascular Medicine", Lippincott Williams & Wilkins, 2000, 109-110