

Temporary Assist Device for Postcardiotomy Cardiac Failure

Antonis A. Pitsis, MD, FETCS,
Petros Dardas, MD, FESC, Nikolaos Mezilis, MD, FESC,
Nikolaos Nikoloudakis, MD,
Gerasimos Filippatos, MD, FESC, and
Daniel Burkhoff, MD, PhD

Thessaloniki Heart Institute, St. Luke's Hospital, Thessaloniki, Greece, Evangelismos General Hospital, Athens, Greece, and Columbia University, New York, New York

Postcardiotomy left ventricular failure (LVF) complicating a cardiac surgical procedure is usually managed with intraaortic balloon pump (IABP) counterpulsation. We report two cases of postcardiotomy LVF unresponsive to inotropic support and IABP counterpulsation that were managed successfully with the use of the TandemHeart percutaneous ventricular assist device (pVAD) (CardiacAssist, Pittsburgh, PA). The TandemHeart pVAD appears to be safe and effective as a bridge to recovery in the treatment of postcardiotomy cardiac failure.

(Ann Thorac Surg 2004;77:1431-3)

© 2004 by The Society of Thoracic Surgeons

Postcardiotomy left ventricular failure (LVF) complicating a cardiac surgical procedure is usually managed with intraaortic balloon pump (IABP) counterpulsation [1]. However, weaning from cardiopulmonary bypass (CPB) is often difficult or impossible despite IABP and inotropic support [2, 3]. Under such conditions, temporary left ventricular assist devices have been used [2-5]. Devices used in the past for this indication generally require surgical implantation and explantation and specially trained personnel [6]. Here, we report our experience with two cases in which postcardiotomy LVF unresponsive to IABP and inotropic support were managed with the TandemHeart percutaneous ventricular assist device (pVAD) (CardiacAssist, Pittsburgh, PA). This system improves the hemodynamic condition of patients by reducing left atrial pressure while increasing mean arterial pressure and cardiac output [7]. These favorable effects are achieved by withdrawing oxygenated blood from the left atrium and returning it to the femoral artery with a simple extracorporeal circuit and centrifugal pump.

Accepted for publication April 18, 2003.

Address reprint requests to Dr Nikoloudakis, Thessaloniki Heart Institute, Ermou St 69, Thessaloniki, Greece; e-mail: nik_nik@freenet.de.

Case Reports

Patient 1

A 61-year-old man with unstable angina was admitted for redo coronary artery bypass grafting operation 10 years after a triple-vessel bypass grafting procedure. He had a history of claudication due to aortoiliac atherosclerotic disease. A preoperative angiogram revealed significant triple-vessel disease with blocked vein grafts to the circumflex and right coronary arteries and a 95% stenosis in a vein graft to the left anterior descending artery (LAD). On beating heart, without CPB (off-pump CAB [OPCAB]), the left internal thoracic artery (LITA) was used to bypass the LAD distally to the previous anastomosis. Also, a reversed saphenous vein graft was anastomosed between the posterior descending artery and the ascending aorta. Our OPCAB technique has been described previously [8]. After completing the anastomoses, ST segment elevation suddenly appeared in the anterior leads. At the same time, the flow through the LITA was measured (Medi-Stim Flowmeter, Medi-Stim AS, Oslo, Norway) and found to be decreased to 4 mL/min from 120 mL/min. This was thought to be the result of the embolization of the LAD from the old vein graft. Cardiopulmonary bypass was established, and the LITA-to-LAD anastomosis was reexplored. The LAD was found to be full of emboli. The heart was arrested using retrograde warm blood cardioplegia in an attempt to wash back the emboli from the distal LAD bed, and the anastomosis was redone. The flow through the LITA returned to 105 mL/min, and the ischemic electrocardiographic alterations disappeared. However, weaning from CPB was not possible despite full inotropic support (epinephrine, norepinephrine, and milrinone). Attempts to insert an IABP from either groin were unsuccessful because of the aortoiliac obliterative disease. An IABP was therefore inserted from the ascending aorta. However, the IABP failed to provide sufficient support to permit separation from CPB, and it was therefore removed. The TandemHeart pVAD was inserted using the right superior pulmonary vein for the insertion of a left atrial cannula (28 F) and the ascending aorta for the arterial cannula (17 F). The pVAD provided 6 L/min output at 6000 rpm, and CPB could be weaned while inotropic and pressor support were reduced. The sternum of the patient was left open, and the skin was closed. The patient was anticoagulated with intravenous heparin at an activated clotting time (ACT) of about 180 seconds. Left ventricular function recovered over the next 4 days, at which point the device was removed, and the patient's chest was closed without the need for any other support. The patient was discharged home on the 15th postoperative day. On follow-up 1 year later, the patient was in New York Heart Association class I and was without angina.

Patient 2

A 67-year-old man with class IV heart failure due to ischemic cardiomyopathy with large anteroseptal and inferior wall myocardial infarctions (left ventricular ejection fraction 15%) and grade 4+ mitral regurgitation was

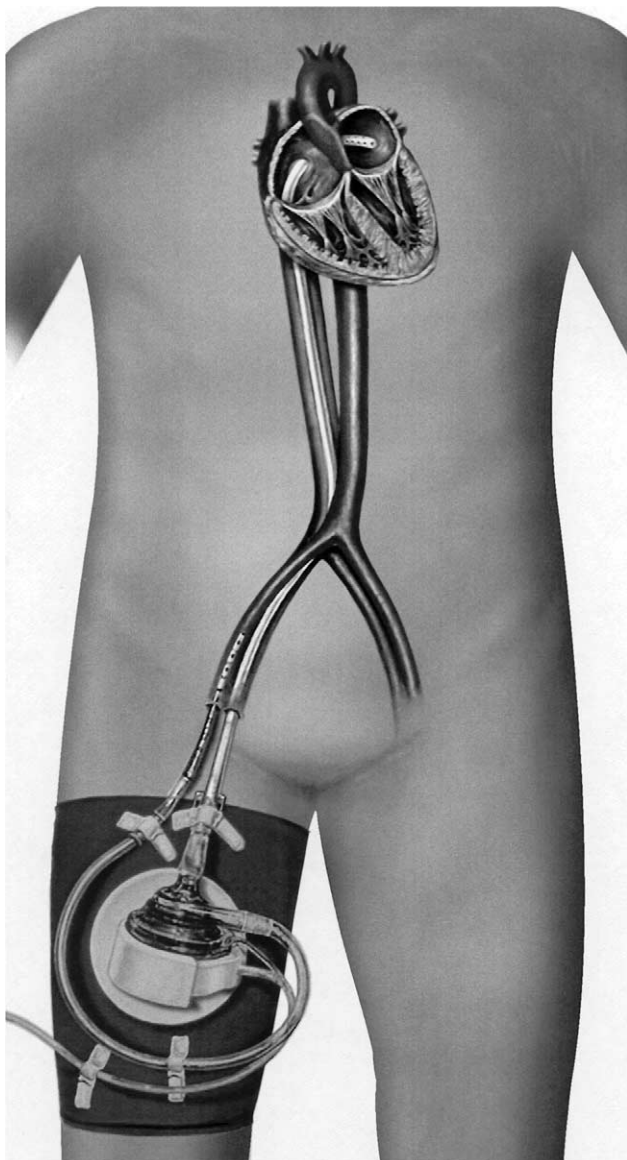


Fig 1. The TandemHeart percutaneous ventricular assist device.

admitted for surgical treatment. While on CPB, the patient underwent a modified Dor procedure (beating heart), a mitral valve repair with an Alfieri stitch, and triple bypass grafting with the LITA to the LAD and saphenous vein grafts to the circumflex and right coronary arteries. Weaning from CPB was impossible despite maximum inotropic and IABP support. The IABP was removed, and a TandemHeart pVAD was inserted. A long 22-F cannula was inserted percutaneously through the right femoral vein and advanced to the left atrium from the right atrium through the foramen ovale. The right femoral artery was cannulated with a 17-F cannula (Seldinger technique) (Fig 1). The TandemHeart pVAD provided 2.5 L/min flow at 6000 rpm, and the patient was weaned from CPB. After CPB, the cardiac index (CI) was found to be 2.5 L · min⁻¹ · m⁻². The ACT was kept at about 180 seconds during the support period. The patient

was extubated on the 3rd postoperative day, and the device was removed on the 11th postoperative day, with hemostasis achieved by applying manual pressure in the groins. After the removal of the device, the CI was 2.6 L · min⁻¹ · m⁻². The patient was discharged on the 30th day but died from ventricular tachycardia 2 months later.

Comment

Intraaortic balloon pumping was introduced more than 30 years ago and since then has been the most widely used means of providing mechanical support to a failing heart in a variety of settings. It has been preferentially used for postcardiotomy low-output syndrome, and it is considered to reduce mortality and morbidity in this setting [1]. When weaning from CPB is not possible despite inotropic and IABP support, a surgeon is left with no choice other than the use of ventricular assist devices (VADs) [2-5]. VADs can offer successful circulatory support, but they are quite expensive and require a second procedure to remove them and specially trained personnel to manage the patients.

The cost of the TandemHeart pVAD is a fraction of that of implantable VADs, although direct comparison is unfair because the latter can provide long-term support. When inserted percutaneously, it can be removed by withdrawing the catheters and applying manual pressure in the groin. This technique is quite similar to the one introduced by Clarence Dennis in the late 1940s and used clinically by Edmunds and colleagues [5], although a different type of pump has been used. The TandemHeart pVAD improves the hemodynamic condition of patients by reducing left atrial pressure while increasing mean arterial pressure and cardiac output. These favorable effects are achieved by withdrawing oxygenated blood from the left atrium and returning it to the femoral artery with a simple extracorporeal circuit and radial pump.

Another major advantage of the TandemHeart pVAD is its versatility. It can be inserted totally percutaneously under fluoroscopic or transesophageal echocardiographic guidance or partially percutaneously with the aid of a right atrial or pulmonary vein incision for the transeptal positioning of the left atrial cannula.

We should also mention that neither of the two patients presented here experienced any bleeding or infective complications or any mechanical device failure.

The TandemHeart pVAD has received the CE mark, which allows its clinical use in Europe. US Food and Drug Administration approval is pending.

In summary, the TandemHeart pVAD appears to be an effective, versatile, and economical VAD as a bridge to postcardiotomy recovery.

References

1. Mehlhorn U, Kroner A, de Vivie ER. 30 years of clinical intra-aortic balloon pumping: facts and figures. *Thorac Cardiovasc Surg* 1999;47(Suppl 2):298-303.
2. Hausmann H, Potapov EV, Koster A, et al. Prognosis after the implantation of an intra-aortic balloon pump in cardiac sur-

- gery calculated with a new score. *Circulation* 2002;106(Suppl 1):I203-6.
- Goldstein DJ, Oz MC. Mechanical support for postcardiotomy cardiogenic shock. *Semin Thorac Cardiovasc Surg* 2000;12:220-8.
 - Golding LA, Crouch RD, Stewart RW, et al. Postcardiotomy centrifugal mechanical ventricular support. *Ann Thorac Surg* 1992;54:1059-63.
 - Edmunds LH Jr, Herrmann HC, DiSesa VJ, Ratcliffe MB, Bavaria JE, McCarthy DM. Left ventricular assist without thoracotomy: clinical experience with the Dennis method. *Ann Thorac Surg* 1994;57:880-5.
 - Helman DN, Morales DL, Edwards NM, et al. Left ventricular assist device bridge-to-transplant network improves survival after failed cardiomy. *Ann Thorac Surg* 1999;68:1187-94.
 - Thiele H, Lauer B, Hambrecht R, et al. Reversal of cardiogenic shock by percutaneous left atrial-to-femoral arterial bypass assistance. *Circulation* 2001;104:2917-22.
 - Pitsis AA, Angelini GD. Off pump coronary bypass grafting of the circumflex artery. *Eur J Cardiothorac Surg* 1999;16:478-9.

Minimally Invasive Direct Coronary Artery Bypass in a Cardiac Transplant Recipient With Allograft Vasculopathy

Ivan Aleksic, MD, PhD, Jarowit A. Piotrowski, MD, Markus Kamler, MD, Ulf Herold, MD, and Heinz G. Jakob, MD, PhD

Department of Thoracic and Cardiovascular Surgery, University Hospital Essen, Essen, Germany

Coronary bypass operation with cardiopulmonary bypass has provided disappointing results for the treatment of cardiac allograft vasculopathy (CAV). We describe a 61-year-old man who underwent heart transplantation for secondary dilated cardiomyopathy in 1995. Consecutively, CAV developed with clinically silent left anterior descending occlusion. After angiographic diagnosis in 1998 he successfully underwent a minimally invasive direct coronary artery bypass procedure. Annual coronary angiography showed a patent left internal mammary to left anterior descending bypass graft more than 4 years after operation. In select cases, minimally invasive direct coronary artery bypass is a therapeutic option for the treatment of CAV.

(*Ann Thorac Surg* 2004;77:1433-4)

© 2004 by The Society of Thoracic Surgeons

Cardiac allograft vasculopathy (CAV) remains the single most important cause of death during long-term follow-up after heart transplantation (HTX) [1]. The experience with conventional bypass operation with cardiopulmonary bypass graft for the treatment of CAV is

Accepted for publication May 21, 2003.

Address reprint requests to Dr Aleksic, Department of Thoracic and Cardiovascular Surgery, University Hospital Essen, Hufelandstr 55, 45122 Essen, Germany; e-mail: ivan.aleksic@uni-essen.de.

limited. Results from 36 bypass graft operations are available [2-6]. The reasons for the scarcity of bypass graft procedures in this setting are the high prevalence of diffusely diseased distal coronary arteries and the high overall perioperative mortality of 35% [2-5]. Pethig and colleagues [6] were the first to report 7 patients without any perioperative mortality after bypass graft operation for CAV. Still, they restrict bypass graft operation and retransplantation to selected patients.

Advantages of minimally invasive direct coronary artery bypass (MIDCAB) grafting include avoidance of cardiopulmonary bypass graft, great vessel manipulation, and re-sternotomy and have facilitated its use in patients undergoing reoperative coronary bypass grafting. Doty and colleagues [7] reported freedom from angina in 90% of patients after reoperative MIDCAB grafting. Stamou and coworkers [8] reported an actuarial survival of 83% with a mean \pm SD follow-up of 2.5 ± 1 years and an operative mortality of 2% after redo MIDCAB procedures.

We describe the case of a 61-year-old man with secondary dilated cardiomyopathy: 3 years after HTX he was diagnosed with left anterior descending (LAD) occlusion and underwent MIDCAB grafting. This is the first case of beating heart revascularization for CAV.

A 61-year-old man underwent orthotopic HTX for secondary dilated cardiomyopathy in 1995 after aortic valve replacement for aortic insufficiency in 1984 and redo aortic valve replacement because of a paravalvular leak in 1989. The donor was a 25-year-old male victim of a motor vehicle accident without any history of hypertension, smoking, or drug abuse.

The recipient's postoperative course was uneventful except for several rejection episodes, which were treated by intravenous steroids. Routine coronary angiography was performed annually and showed beginning CAV within 2 years after transplantation. In October 1998 another follow-up angiogram demonstrated clinically silent proximal LAD occlusion. The occlusion was not amenable to any cardiologic intervention. Coronary flow reserve in the circumflex artery (CX) had decreased from 4.0 the year before to 2.3, indicating progression of CAV. Coronary flow reserve in the right coronary artery was 4.3. Scintigraphy revealed viable myocardium in the septum and the apex.

Faced with a third conventional reoperation, we decided to perform a MIDCAB procedure by way of a small anterior approach through the left fourth intercostal space. The LAD had a thickened wall, and the left internal mammary artery was anastomosed to the LAD with a 7-0 running suture. The patient's postoperative course was unremarkable, and he was discharged home on postoperative day 6.

Annual angiographic studies were continued and showed progression of his CAV in the CX. The latest angiogram, from January 2003 (Fig 1), showed a patent left internal mammary artery-LAD bypass graft without any anastomotic stenosis. A circumscribed lesion in segment 13 of